

## Patella Maltracking

Mark Locke, MD, FAAP  
mark.locke@mooreclinic.com

**Definition-** Patella maltracking is a very common cause of knee pain in adolescents. The knee cap (patella) is designed to track up and down in the trochlear groove of the femur (upper leg bone). For various reasons the patella can track out of its groove (usually pulled laterally). The condition is much more common in females. Patella mal-tracking is usually an overuse type injury, but can be a result of trauma to the knee (subluxation or dislocation).

### **Synonyms-**

- Patellofemoral syndrome
- Patella subluxation

**Clinical symptoms-** The young patient usually presents with anterior knee pain, sometimes localized to the medial aspect of the patella (inside). Patients often note going up or down stairs worsens the problem, as does sitting for a prolonged period (theater sign). Many times there is a recent history of increased physical activity (i.e. running).

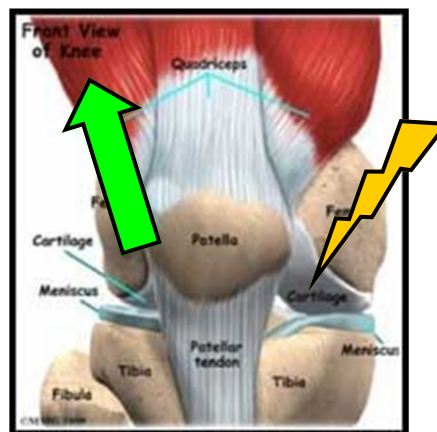
**Physical exam-** The patient may show the typical “miserable malalignment syndrome” with a relatively wide pelvis, genu valgum (knocked kneed), and flat feet. The patient may have a “mobile” patella, or a patella sitting higher than normal (patella alta). Usually the pain is most pronounced palpating along the medial aspect of the knee cap (medial retinaculum) and is made worse by physically pushing the patella laterally out of the groove (apprehension sign). The muscles on the outside of the leg are often more developed than those of the inside (VMO).

**Diagnostic tests-** This is a common condition and in most cases only the history and physical exam are required to make the diagnosis. If the condition has been going on for some time or there is a history of trauma, XRs help to rule out other causes of knee pain. Further testing (i.e. MRI) is rarely indicated unless the condition is not responding to conservative treatment measures.

### **Differential diagnosis-**

- Plica band syndrome
- Patella or quad tendonitis
- Medial meniscal injury
- Medial collateral ligament sprain

**Treatment-** Conservative treatment measures include relative rest (limiting activities which cause pain), ice (especially after activity), and anti-inflammatory medicines (motrin or naproxen). Stationary biking is a good activity to try first. Raising the seat slightly higher than normal helps decrease stress at the knee. Physical therapy is often helpful to improve the strength of the VMO muscle. Taping (McConnell) and various knee braces may be tried to help maintain the patella in its groove. For those patients that fail conservative approaches, surgery may be indicated. It is important to point out that surgery is not a “cure all” and all of the above modalities must be continued after surgery. If the patient has flat feet this must be addressed with supportive shoes or orthotics.



### **Dr. Locke's clinical care team**

Tammie Gillam 227-8176  
tammie.gillam@mooreclinic.com

Lacey Davis 227-8158  
lacey.davis@mooreclinic.com